

REVIEW ARTICLE

Dan L. Longo, M.D., *Editor*

Sciatica

Allan H. Ropper, M.D., and Ross D. Zafonte, D.O.

From Brigham and Women's Hospital (A.H.R.) and Spaulding Rehabilitation Hospital (R.D.Z.) — both in Boston.

N Engl J Med 2015;372:1240-8.

DOI: 10.1056/NEJMra1410151

Copyright © 2015 Massachusetts Medical Society.

THE MUNDANE MALADY SCIATICA HAS BEEN KNOWN TO PHYSICIANS SINCE antiquity.¹ It is pain that radiates from the buttock downward along the course of the sciatic nerve,² but the term has been used indiscriminately for a variety of back and leg symptoms. Although sciatica has several causes, Mixter and Barr extended previous observations to establish in 1934 that the principal source is compression of a lumbar nerve root by disk material that has ruptured through its surrounding annulus (see the Glossary).³ Neuroradiologic studies affirm that 85% of cases of sciatica are associated with a disk disorder.⁴

ANATOMY OF THE SCIATIC NERVE

The fourth and fifth lumbar nerve roots and the first two sacral nerve roots join in the lumbosacral plexus to form the peroneal and tibial nerves that leave the pelvis in an ensheathed single trunk as the sciatic nerve, the largest nerve in the body. Disturbances anywhere along the course of the sciatic nerve can give rise to sciatica, but the most common areas are at the sites of disk rupture and osteoarthritic change — at the L4–L5 and L5–S1 levels and, less frequently, the L3–L4 level — where there is usually compression of the root below the corresponding disk. The mechanism of sciatica may relate to distortion of the nerve root or its sensory ganglion⁵ or putatively to the effect of local inflammatory cytokines. Other sites of sciatic injury are in the lower pelvic cavity, buttock, gluteal fold, and proximal biceps femoris muscle (Fig. 1). The prevalence of sciatica varies widely among studies, with a highest incidence of 40%. Most instances occur in the fourth and fifth decades of life.⁶

SYMPTOMS AND EXAMINATION FINDINGS

Sciatica may begin either suddenly with physical activity or slowly. Sciatic pain has aching and sharp components and radiates along a broad line from the middle or lower buttock, proceeding dorsolaterally in the thigh in cases of compression of the L5 nerve root and posteriorly in cases of compression of S1. With L4 compression, the pain is anterolateral in the thigh and may be misattributed to hip disease. If nerve-root pain extends below the knee, its location conforms to the superficial sensory distribution of the affected spinal root. Sciatica is usually unilateral, in keeping with the common dorsolateral configuration of disk rupture and with foraminal stenosis from osteoarthritic disease of the spine. There may be bilateral pain in central disk herniation, lumbar stenosis, and spondylolisthesis.

Low back pain of variable severity accompanies sciatica but is not a consistent feature. Aching in the L5–S1 area or in the upper sacroiliac joint is common with disk rupture. Increased back and sciatic pain with coughing, sneezing, straining, or other forms of the Valsalva maneuver suggests disk rupture. Depending on the site

Glossary

Annulus: The annulus is the connective tissue surrounding the spinal disk.

Biceps femoris: This muscle is also known as the hamstring muscle.

Fibrillations: Fibrillations are spontaneous short-duration electrical potentials of single muscle fibers seen on electromyography and caused by denervation of muscle. They are not visible by observing the surface of the skin.

Foraminal stenosis: This term refers to narrowing of the canal of exit of spinal nerve roots.

Late responses (F-wave and H-reflex): The F-wave is an elicited electrical response of the anterior horn cell to supra-maximal stimulation of a motor nerve. An antidromic stimulus of the motor axon depolarizes the anterior horn cell and causes an orthodromic potential that appears as a second motor action potential after the initial compound motor action potential. The H-reflex is the electrical representation of the ankle reflex. The F-wave and the H-reflex are useful because they are conducted through the spinal nerve root and proximal nerve and are therefore sensitive to compression by a disk.

Nocifensive response: This response is an involuntary, defensive muscular reaction that prevents use or movement of a painful body part.

Sciatic notch (greater sciatic notch): The sciatic notch is the point of exit of the sciatic nerve under the ischial spine at the pelvic brim.

Sharp waves: Sharp waves are similar to fibrillations but appear earlier. Both types of electrical potentials take weeks or longer to appear after damage to a motor axon.

Spondylolisthesis: Spondylolisthesis is displacement (subluxation) of a vertebral body and its posterior elements from its normal alignment.

and size of the rupture, the patient may adopt a posture of ventroflexion and either reduced or exaggerated lumbar lordosis, minimizing pressure on the root. Bilateral sciatica that is brought on by walking and simulates vascular claudication is the result of compression of the cauda equina roots. Such compression is known as neurogenic claudication (the Verbiest syndrome).

Patients may have paresthesias in the dermatomal distribution of a nerve root, but sensory symptoms and signs are not prominent. Weakness is present in less than half of patients but is infrequently severe enough to cause foot drop (in cases of L5 radiculopathy) or a downward tilted pelvis during walking (in cases of gluteal weakness due to compression of S1). Compression of the S1 nerve root is usually associated with reduction in or loss of the ankle reflex, and L3 or L4 compression is associated with variable reduction in the knee reflex; L5 compression causes inconsistent changes in reflexes. There are frequently unanticipated variations of these reflex patterns.

Many clinical tests have been devised to determine whether sciatic pain is caused by disk compression of a spinal nerve root; most of the tests are variations of the straight-leg-raising test (Lasègue's test) (Fig. 2). In a patient in the supine position, raising the leg with the knee extended stretches the nerve root over the protruded disk and results in a nocifensive response of muscle

contraction. A positive test consists of reproduction or marked worsening of the patient's initial pain and firm resistance to further elevation of the leg. A diagnosis of disk compression is likely if pain radiates from the buttock to below the knee when the angle of the leg is between 30 and 70 degrees. Sensitivity of the test for disk herniation is approximately 90%, but specificity is low.⁷ Many persons without spinal abnormalities have hamstring and gluteal tightness with discomfort elicited by straight-leg raising, but the pain is more diffuse than in sciatica and the leg can be lifted higher if the maneuver is performed slowly. Increased pain on dorsiflexion of the foot or large toe increases sensitivity. The crossed straight-leg-raising test (Fajersztajn's test) involves raising the unaffected leg; in a positive test, sciatic pain is elicited in the opposite (affected) leg. This test is 90% specific for disk herniation on the contralateral side but is insensitive.⁷

IMAGING AND
ELECTROPHYSIOLOGICAL TESTING

Imaging and electrophysiological evidence of nerve-root compression corroborates structural disk or spine disease as the proximate cause of sciatica, but testing is not necessary in a typical case until intervention is required. Radiographs of the lumbar spine provide limited information, but they may show reduction in the height of an

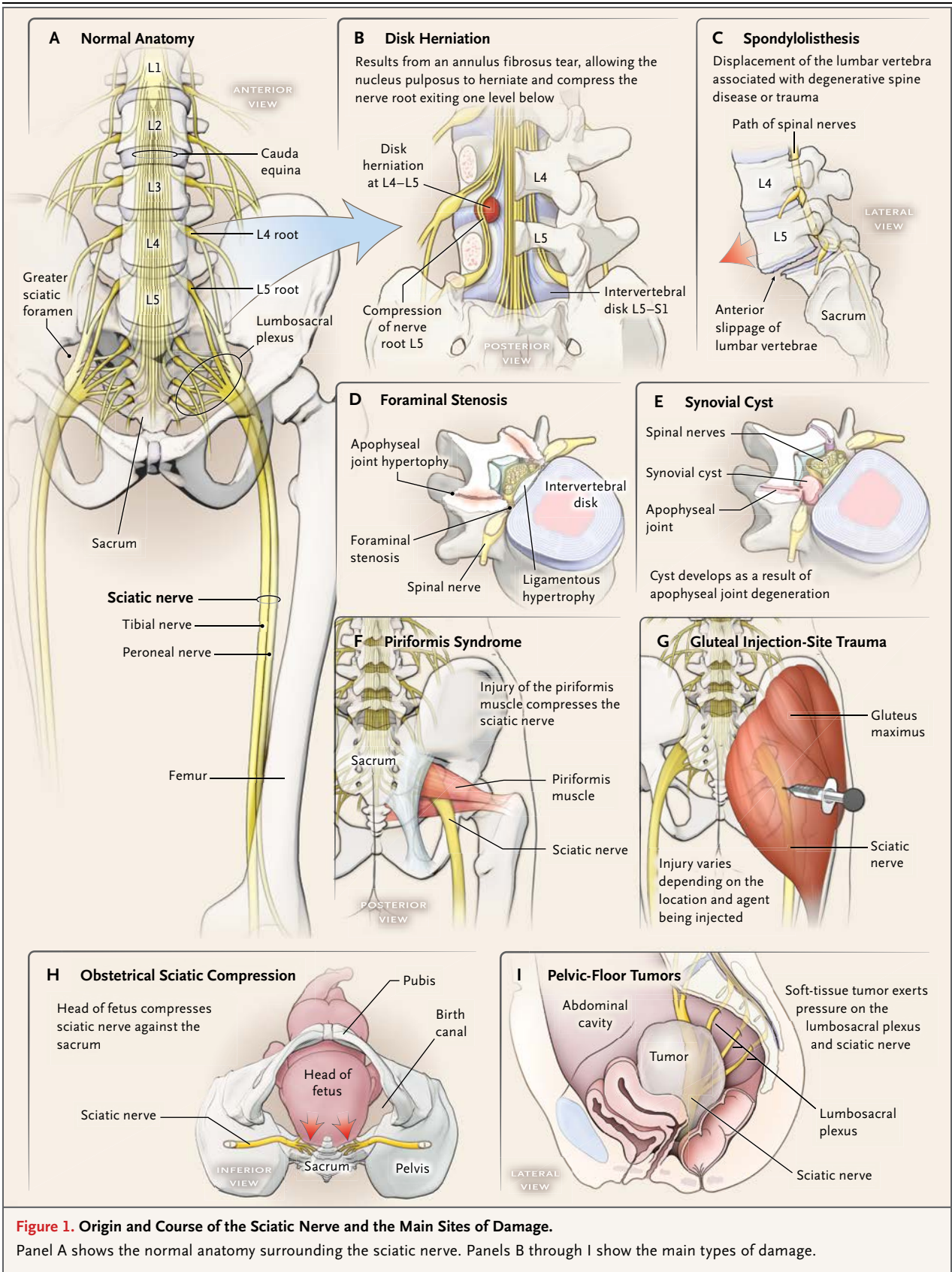
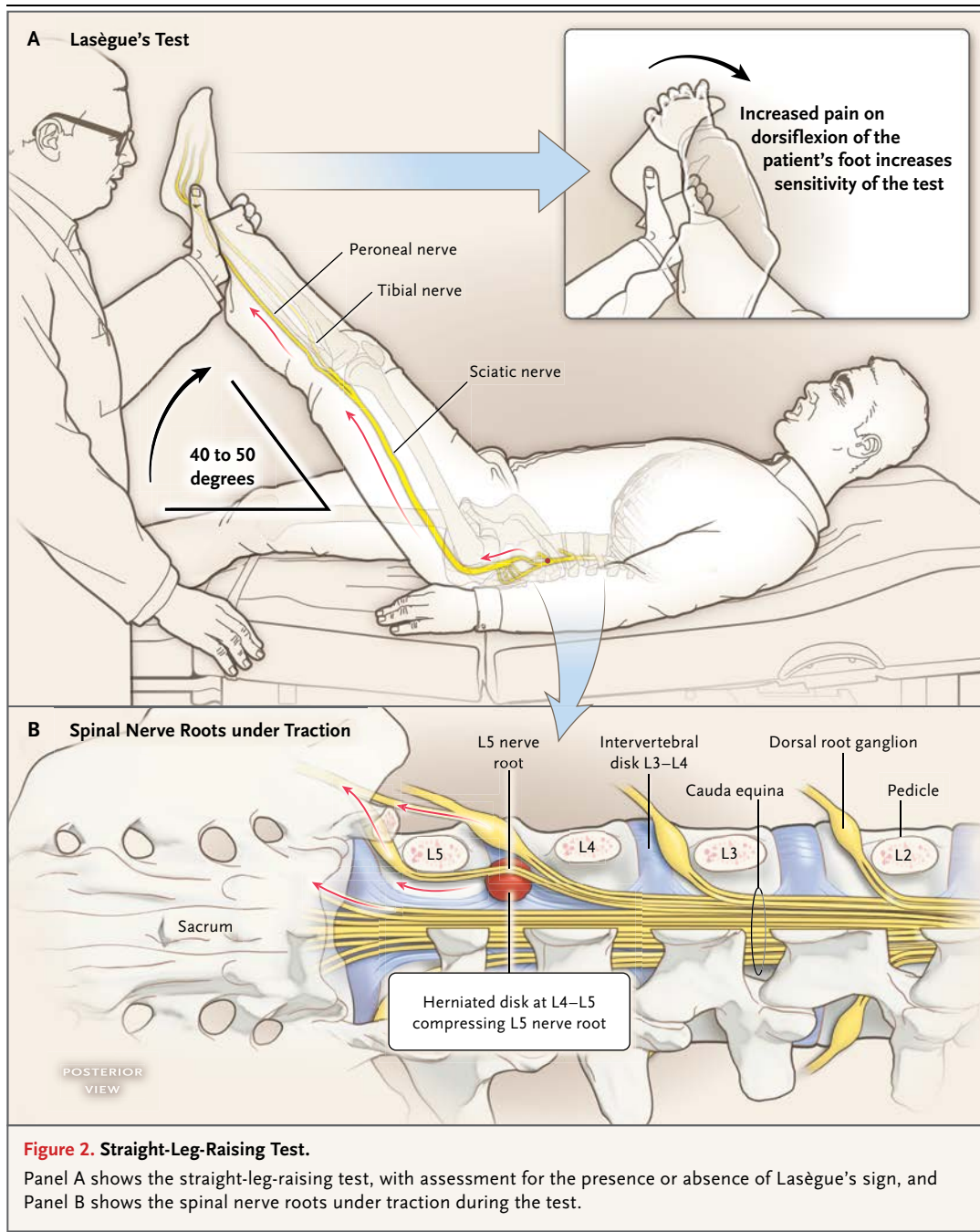


Figure 1. Origin and Course of the Sciatic Nerve and the Main Sites of Damage.

Panel A shows the normal anatomy surrounding the sciatic nerve. Panels B through I show the main types of damage.



intervertebral space, spondylolisthesis, osteomyelitis, or tumor infiltration of a vertebral body. The nature and location of disk rupture and spinal lesions, such as osteoarthritic disease and spondylolisthesis, lateral recess stenosis, and synovial cysts of the facet joint, can be accurately seen on magnetic resonance imaging (MRI) without the administration of gadolinium (Fig. 3).

Computed tomography (CT) is performed less frequently but reveals most disk herniations and structural changes of the spine. CT and MRI each have a role in exploration of the pelvic fossa when sciatic compression is suspected in those regions. Disk bulging and related minor deformities generally do not cause compression of nerve roots and are not an explanation for persistent sciati-

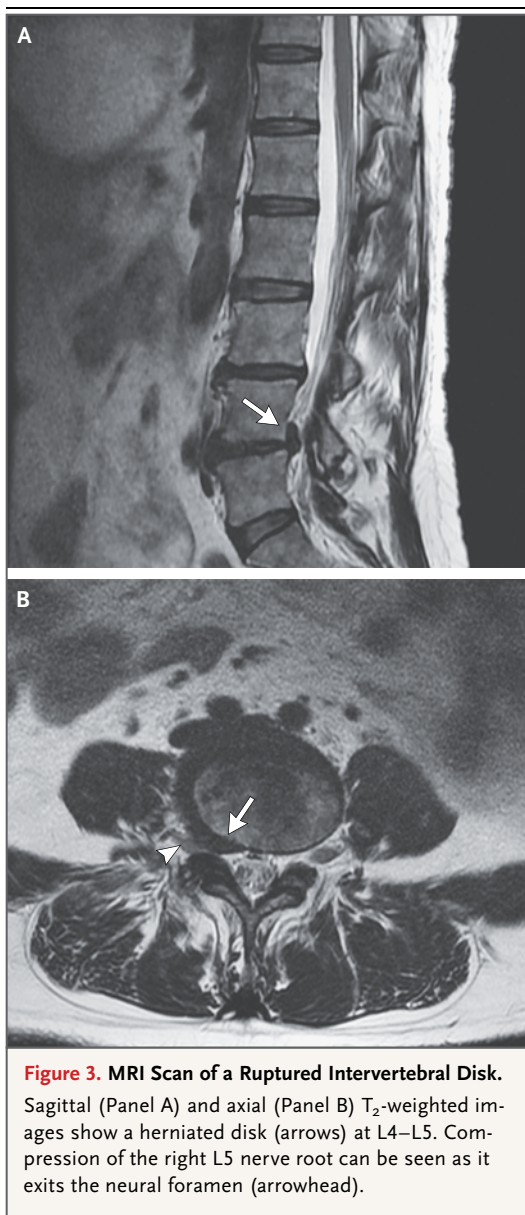


Figure 3. MRI Scan of a Ruptured Intervertebral Disk. Sagittal (Panel A) and axial (Panel B) T₂-weighted images show a herniated disk (arrows) at L4–L5. Compression of the right L5 nerve root can be seen as it exits the neural foramen (arrowhead).

ca. The clinician should be aware that a high rate of minor abnormalities are seen on MRI in patients without back or radicular symptoms but that disk rupture is seen in less than 1% of asymptomatic patients.⁸

Needle electromyography (EMG) and nerve-conduction studies aid diagnosis by revealing a topographic distribution of muscular denervation corresponding to a nerve root. Denervation becomes apparent days or weeks after injury, and the appearance of changes takes longer in distal than in proximal muscles. The most specific

findings are fibrillations and sharp waves in muscles corresponding to a single nerve root, combined with normal sensory potentials from nerves that carry that root; the latter is the result of the preganglionic site of root compression, leaving the cell body and distal axon unaffected. Sampling four or five relevant muscles including the paraspinal regions is considered adequate.⁹ Late responses are often included in the nerve-conduction studies because they are sensitive to root compression. Electrodiagnostic confirmation that sciatica is due to a radiculopathy rather than to an undefined musculoskeletal problem is associated with a better outcome,¹⁰ but the role of EMG in sciatica has not been established and some guidelines do not require testing.

NONSPINAL CAUSES OF SCIATICA

Sciatica due to disk rupture and degenerative spine disease is more common than sciatica due to all nonspinal causes taken together (Table 1 and Fig. 1). Hip disease and sciatica are likely to be mistaken for each other.

PIRIFORMIS SYNDROME AND BACK-POCKET SCIATICA

The piriformis syndrome has been attributed to compression of the sciatic nerve underlying the piriformis muscle, which stabilizes and serves as an external rotator of the hip. Although the nature and frequency of the syndrome are uncertain, the most consistent features, derived from a systematic review,¹¹ are focal mid-buttock pain, tenderness over the sciatic notch, aggravation of pain after sitting, and provocation with maneuvers that increase piriformis muscle tension such as external rotation of the hip. Pain with the straight-leg-raising maneuver was reported in a meta-analysis to occur in approximately half of cases. It is presumed that an injured piriformis muscle, sometimes caused by running, stretching, or lunging, compresses the sciatic nerve, but the pathophysiology is unclear. Electrodiagnostic and imaging tests are usually normal.

In the mid-20th century, as wallets expanded in capacity, sciatica (“credit-carditis”) that was cured by removal of the wallet from the back pocket became the subject of anecdotal reports.^{12,13} Tools, cell phones, and golf balls in back pockets and prolonged sitting on hard surfaces, including car seats, can also produce sciatica.

ZOSTER SINE HERPETE

For the first few days before the eruption of shingles in a lumbar or upper sacral dermatome, herpes zoster reactivation closely simulates sciatica caused by disk rupture. Diagnosis is difficult in the intervening days and especially in the few instances in which the rash never develops.

TRAUMATIC INJURY OF THE SCIATIC NERVE

Traumatic injury of the sciatic nerve occurs with fractures of the pelvis or after proximal hamstring injury and with extreme stretching of the nerve. Muscle hematomas or tendinous injuries may cause severe sciatica. Posterior hip dislocation or femoral fracture impinge on the nerve; sciatica may also occur during relocation of the hip joint. Injection-site damage in the buttocks is a self-evident but infrequent cause.

GYNECOLOGIC AND PERIPARTUM CAUSES

Deposits of endometrial tissue on the proximal nerve can cause recurrent cyclic, or catamenial, sciatica, more often on the right side than on the left side.¹⁴ Large ovarian cysts and uterine enlargement associated with late pregnancy can compress the nerve between the fetal head and the pelvic brim (Fig. 1). It is not unusual for a woman to have unilateral or bilateral sciatica post partum, regardless of whether forceps were used during delivery; sciatica ostensibly occurs after a woman has spent a prolonged time in the lithotomy position.

CONSERVATIVE TREATMENT OF SCIATICA

Sciatica resolves without treatment in the majority of cases. Numerous systematic analyses have compared various forms of therapy for sciatica, but the validity of their constituent studies is limited.¹⁵⁻¹⁷ Many conflate treatment for back pain with that for sciatica. Although it is difficult to derive clinically useful information from these compilations, they do provide some perspective on the relative value of treatments.

The most common initial treatment is pain control by means of medication and physical therapy. Activity is usually self-limited in proportion to the degree of discomfort, and although rest is often recommended, it is not better than movement in patients who are able to remain active.¹⁸ Nonsteroidal antiinflammatory medica-

Table 1. Causes of Sciatica and of Conditions Simulating Sciatica.

<p>Spinal causes</p> <ul style="list-style-type: none"> Disk rupture with compression of L4, L5, or S1 root Osteoarthritic impingement on roots due to spondylolisthesis or foraminal or lumbar stenosis Synovial cyst of facet joint Arachnoid (Tarlov) cyst Tumors of the spinal column Neurofibromas on lumbar and sacral nerve roots Arachnoiditis <p>Nonspinal causes</p> <ul style="list-style-type: none"> Pelvic and gynecologic conditions, including cyclic sciatica due to endometriosis Piriformis syndrome and back-pocket sciatica Pregnancy, delivery, and prolonged time in the lithotomy position Zoster sine herpete Diabetic radiculopathy Gluteal injection-site trauma Lumbar plexitis Vascular impingement on sciatic nerve (pseudoaneurysm of the inferior gluteal artery) Hip fracture and dislocation or relocation; extensive pelvic fractures Biceps femoris hematoma, strain, and tear Idiopathic causes in young persons

tions may provide short-term relief for low back and sciatic pain; however, it is difficult to determine their effect on sciatica,¹⁵ and many patients report little relief. Orally or systemically administered glucocorticoids have been used to ameliorate sciatica, but it is difficult to interpret their effect.¹⁵⁻¹⁷ Many guidelines recommend restrictions on the use of opioids. Antiepileptic drugs, gabapentin, pregabalin, antidepressant agents (e.g., tricyclic agents), muscle relaxants, and pain medications have been used but with little supporting data.

Any intervention that temporarily reduces pain and increases participation in exercises, even if it is associated with no long-term benefit, could play a role in care. The benefits of physical therapy and various exercise regimens are difficult to determine, and the superiority of any one program has not been established, although most appear to be safe. Programs include directional preference exercises (back-movement exercises in a direction that causes the locus of pain to move proximally,

toward the mid-back, where it is better tolerated),¹⁹ motor-control exercises (also known as specific stabilization exercises) that focus on enhancing control of the transversus abdominis and multifidus muscles, which stabilize the spine, strengthening of other core muscles, stretching, general fitness exercises, and yoga. One conventional approach involves slowly increasing mobilization of the lumbar spinal segments by means of stretching and exercise, improving posture, and strengthening the muscles that stabilize the spinal column and pelvis. It has been difficult to show that this approach accelerates recovery or prevents future injury, but some trials suggest that it is superior to rest in the acute phase of sciatica.²⁰

Spinal manipulation for sciatica is widely used and has been studied with an assortment of designs and comparators; therefore, reviews of existing trials, most considered of low or moderate quality, draw limited conclusions.^{16,17,21} One recent pragmatic trial for subacute or chronic back and leg pain has suggested that spinal manipulation provides a short-term benefit when added to an exercise program.²² Lumbar traction was used in the past, particularly if low back pain was prominent, but a review of available studies, most of low and moderate quality, showed no advantage.²³ Transcutaneous electrical nerve stimulation is probably ineffective.²⁴ Acupuncture has been proposed for persistent sciatic discomfort, but its efficacy has not been shown.^{15,16} Chemonucleolysis of an extruded disk had positive results in some studies and systematic analyses but is infrequently used.

Epidural injections of glucocorticoids are frequently administered for low back pain and related conditions. Trials have suggested an associated short-term decrease in leg pain but no decrease in the need for subsequent surgery.^{16,17,25} There is no clear difference in efficacy between fluoroscopically guided translaminar and transforaminal injections, but some guidelines endorse one technique over the other. In experimental studies and preliminary clinical trials, biologic agents such as tumor necrosis factor inhibitors have shown negative or limited positive effects on leg pain.²⁶

Treatment of the piriformis syndrome involves stretching and physical therapy to enhance mobility. Injections into the muscle are sometimes administered under fluoroscopic, electromyographic, or ultrasonographic guidance; the use of glu-

cocorticoids and botulinum toxin has been examined alone and in combination with physical therapy, with the suggestion that botulinum toxin may be more helpful than either placebo or injections containing a combination of lidocaine and a glucocorticoid in relieving discomfort,²⁷ but support for any of these treatments is weak.

SURGICAL TREATMENT OF SCIATICA CAUSED BY LUMBAR DISK DISEASE

Sciatica resolves without treatment in one third of patients within 2 weeks and in three quarters of patients within 3 months after onset.²⁸ Nevertheless, most trials comparing surgical treatment and conservative treatment of sciatica due to lumbar disk disease favor surgery, because it results in earlier relief of pain. One representative study showed that patients who had sciatica for 6 to 12 weeks and were assigned to lumbar disk surgery had faster and more pronounced pain relief than those assigned to conservative treatment. However, 1 year after surgery, there were few differences in pain or disability between the two groups.²⁹ The trial also showed that 39% of patients initially assigned to conservative therapy required surgery after a median of 14 weeks of pain, and in a 5-year follow-up study, an additional 7% requested surgery.³⁰ One may conclude that surgery produces faster pain relief and accelerates improvement in mobility but that postponement of surgery to determine whether pain will abate is appropriate. It is not known whether delaying surgery in persons with weakness reduces the chance of full recovery or allows time for weakness to resolve. Surgery has been recommended in cases of large disk ruptures into the spinal canal that compress the cauda equina and cause failure of the bladder sphincter or the bowel sphincter.

In a cost-effectiveness study of prolonged conservative care versus early surgery, the shortened duration of pain after discectomy correlated with a cost savings per quality-adjusted life-year of approximately \$60,000.³¹ In that study, 23% of the participants reverted from recovered to not recovered or vice versa at various times over a 5-year period, which indicates that sciatica can be a chronic and relapsing symptom. In another study, the configuration of the disk on MRI 1 year after the onset of symptoms did not distinguish between patients in whom sciatica had improved and those in whom it had not improved; inexpli-

cably, this was true for patients who underwent surgical treatment and for those who underwent conservative treatment.³²

SURGICAL TECHNIQUES

Treatment of sciatica by means of decompression of a lumbar nerve root is most likely to succeed if symptoms conform to the typical clinical pattern and imaging studies show disk rupture. Several open and percutaneous surgical approaches have been devised. A unilateral hemilaminotomy (removing parts of adjacent laminae on the side that needs to be decompressed) is usually adequate. In the past, bilateral laminectomy, a more extensive procedure, was performed, but the unilateral procedure is favored because it preserves tension and alignment between adjacent spinal segments. Microdiscectomy and various minimally invasive and percutaneous techniques involving, for example, a series of tubular retractors or an endoscope, are also used to treat disk rupture.

The sequestered disk fragment or larger amounts of the intra-annular disk may be removed. Fusion of adjacent spinal segments is generally not necessary if there is no mobile spondylolisthesis and the operation is at one level. In pooled analyses, there is little evidence that any technique, minimally invasive or conventional, produces better results than any other technique.³³ Minimally invasive approaches show a trend toward earlier and better pain relief, probably because there is less paraspinal muscle damage, but according to a meta-analysis, they require longer operating times and are associated with a higher rate of rerupture of the disk³⁴ and therefore may not be appropriate in all cases. Complications of surgery are infrequent but include dural tears with leakage of cerebrospinal fluid, as well as damage to the root or cauda equina. The use of hardware to prevent instability and chronic low back pain is often necessary in cases of spinal stenosis, in which multilevel operations or those involving wide resection of bone are typically performed.

GUIDELINES AND SYSTEMATIC REVIEWS

Despite the numerous guidelines and systematic reviews that have been published regarding the

treatment of low back pain in patients with and in those without sciatica, the outcomes and the cost of care have remained unchanged for more than a decade.³⁵ A review of major trials with adequate data for analysis concluded that there was conflicting evidence on long-term benefit but that surgery relieved pain more rapidly and to a greater degree than did conservative therapy.³⁶

A discursive analysis by the National Institute of Health Research, in the United Kingdom, about the effectiveness of various strategies to manage sciatica^{15,37} showed some support for almost all current treatments, including disk surgery, epidural glucocorticoids, chemonucleolysis, and alternative therapies. However, only surgery benefitted all aspects of global effect, pain relief, and a composite of condition-specific outcomes in the short, medium, and long term.

North American Spine Society guidelines³⁸ state that discectomy provides more effective and more rapid symptom relief than do other treatments for symptoms that warrant surgery, although less severe symptoms can be managed conservatively; patients with psychological distress have poor outcomes after surgery; epidural glucocorticoid injection provides short-term pain relief; electrodiagnostic studies have limited utility; and for many technical aspects of surgery, such as lumbar fusion, there was insufficient evidence for comment. The guidelines also indicate that there is inadequate evidence to gauge how long one can wait before surgery and still recover from cauda equina compression or motor deficits.

British Pain Society guidelines for the treatment of low back pain and radicular pain³⁹ broadly reflect other analyses in separating the plans for radicular pain from those for low back pain and acknowledge that the recommendations lack precision. According to the British Pain Society, any indication of cauda equina compression requires referral for urgent surgery. Severe radicular pain that is disabling or intrusive or that prevents the patient from performing everyday tasks requires MRI, as does a persistent neurologic deficit that lasts 2 weeks. MRI should be ordered by clinicians who can interpret the results; it is discouraged at the primary care level.

No potential conflict of interest relevant to this article was reported.

Disclosure forms provided by the authors are available with the full text of this article at NEJM.org.

REFERENCES

1. Pearce JMS. A brief history of sciatica. *Spinal Cord* 2007;45:592-6.
2. Frymoyer JW. Back pain and sciatica. *N Engl J Med* 1988;318:291-300.
3. Mixter WJ, Barr JS. Rupture of the intervertebral disk with involvement of the spinal canal. *N Engl J Med* 1934;211:210-5.
4. Porchet F, Wietlisbach V, Burnand B, Daepfen K, Villemure JG, Vader JP. Relationship between severity of lumbar disc disease and disability scores in sciatica patients. *Neurosurgery* 2002;50:1253-9.
5. Lindblom K, Rexed B. Spinal nerve injury in dorso-lateral protrusions of lumbar discs. *Neurosurgery* 1948;5:413-32.
6. Konstantinou K, Dunn KM. Sciatica: review of epidemiological studies and prevalence estimates. *Spine (Phila Pa 1976)* 2008;33:2464-72.
7. van der Windt DA, Simons E, Riphagen II, et al. Physical examination for lumbar radiculopathy due to disc herniation in patients with low-back pain. *Cochrane Database Syst Rev* 2010;2:CD007431.
8. Jensen MC, Brant-Zawadzki MN, Obuchowski N, Modic MT, Malkasian D, Ross JS. Magnetic resonance imaging of the lumbar spine in people without back pain. *N Engl J Med* 1994;331:69-73.
9. Tsao BE, Levin KH, Bodner RA. Comparison of surgical and electrodiagnostic findings in single root lumbosacral radiculopathies. *Muscle Nerve* 2003;27:60-4.
10. Savage NJ, Fritz JM, Kircher JC, Thackeray A. The prognostic value of electrodiagnostic testing in patients with sciatica receiving physical therapy. *Eur Spine J* 2014 July 22 (Epub ahead of print).
11. Hopayian K, Song F, Riera R, Sambandan S. The clinical features of the piriformis syndrome: a systematic review. *Eur Spine J* 2010;19:2095-109.
12. Battle JD. "Credit-carditis" — a new clinical entity? *N Engl J Med* 1966;274:467.
13. Gould N. Back-pocket sciatica. *N Engl J Med* 1974;290:633.
14. Forrest JS, Brooks DL. Cyclic sciatica of endometriosis. *JAMA* 1972;222:1177-8.
15. Lewis RA, Williams NH, Sutton AJ, et al. Comparative clinical effectiveness of management strategies for sciatica: systematic review and network meta-analyses. *Spine J* 2013 October 4 (Epub ahead of print).
16. Luijsterburg PA, Verhagen AP, Ostelo RW, van Os TA, Peul WC, Koes BW. Effectiveness of conservative treatments for the lumbosacral radicular syndrome: a systematic review. *Eur Spine J* 2007;16:881-99.
17. Valat JP, Genevay S, Marty M, Rozenberg S, Koes B. Sciatica. *Best Pract Res Clin Rheumatol* 2010;24:241-52.
18. Vroomen PC, de Krom MC, Wilmink JT, Kester AD, Knottnerus JA. Lack of effectiveness of bed rest for sciatica. *N Engl J Med* 1999;340:418-23.
19. Surkitt LD, Ford JJ, Hahne AJ, Pizzari T, McMeeken JM. Efficacy of directional preference management for low back pain: a systematic review. *Phys Ther* 2012;92:652-65.
20. Kennedy DJ, Noh MY. The role of core stabilization in lumbosacral radiculopathy. *Phys Med Rehabil Clin N Am* 2011;22:91-103.
21. Leininger B, Bronfort G, Evans R, Reiter T. Spinal manipulation or mobilization for radiculopathy: a systematic review. *Phys Med Rehabil Clin N Am* 2011;22:105-25.
22. Bronfort G, Hondras MA, Schulz CA, Evans RL, Long CR, Grimm R. Spinal manipulation and home exercise with advice for subacute and chronic back-related leg pain: a trial with adaptive allocation. *Ann Intern Med* 2014;161:381-91.
23. Wegner I, Widyahening IS, van Tulder MW, et al. Traction for low-back pain with or without sciatica. *Cochrane Database Syst Rev* 2013;8:CD003010.
24. Buchmuller A, Navez M, Millette-Bernardin M, et al. Value of TENS for relief of chronic low back pain with or without radicular pain. *Eur J Pain* 2012;16:656-65.
25. Carette S, Leclaire R, Marcoux S, et al. Epidural corticosteroid injections for sciatica due to herniated nucleus pulposus. *N Engl J Med* 1997;336:1634-40.
26. Genevay S, Viatte S, Finckh A, Zufferer P, Balagué F, Gabay C. Adalimumab in severe and acute sciatica: a multicenter, randomized, double-blind, placebo-controlled trial. *Arthritis Rheum* 2010;62:2339-46.
27. Fishman LM, Anderson C, Rosner B. BOTOX and physical therapy in the treatment of piriformis syndrome. *Am J Phys Med Rehabil* 2002;81:936-42.
28. Vroomen PC, de Krom MC, Knottnerus JA. Predicting the outcome of sciatica at short-term follow-up. *Br J Gen Pract* 2002;52:119-23.
29. Peul WC, van Houwelingen HC, van den Hout WB, et al. Surgery versus prolonged conservative treatment for sciatica. *N Engl J Med* 2007;356:2245-56.
30. Lequin MB, Verbaan D, Jacobs WCH, et al. Surgery versus prolonged conservative treatment for sciatica: 5-year results of a randomised controlled trial. *BMJ Open* 2013;3(5):e002534.
31. van den Hout WB, Peul WC, Koes BW, Brand R, Kievit J, Thomeer RT. Prolonged conservative care versus early surgery in patients with sciatica from lumbar disc herniation: cost utility analysis alongside a randomised controlled trial. *BMJ* 2008;336:1351-4.
32. el Barzouhi A, Vleggeert-Lankamp CL, Lycklama à Nijeholt GJ, et al. Magnetic resonance imaging in follow-up assessment of sciatica. *N Engl J Med* 2013;368:999-1007.
33. Jacobs WC, Arts MP, van Tulder MW, et al. Surgical techniques for sciatica due to herniated disc, a systematic review. *Eur Spine J* 2012;21:2232-51.
34. Chang X, Chen B, Li HY, Han XB, Zhou Y, Li CQ. The safety and efficacy of minimally invasive discectomy: a meta-analysis of prospective randomised controlled trials. *Int Orthop* 2014;38:1225-34.
35. Mafi JN, McCarthy EP, Davis RB, Landon BE. Worsening trends in the management and treatment of back pain. *JAMA Intern Med* 2013;173:1573-81.
36. Jacobs WC, van Tulder M, Arts M, et al. Surgery versus conservative management of sciatica due to a lumbar herniated disc: a systematic review. *Eur Spine J* 2011;20:513-22.
37. Lewis R, Williams N, Matar HE, et al. The clinical effectiveness and cost-effectiveness of management strategies for sciatica: systematic review and economic model. *Health Technol Assess* 2011;15:1-578.
38. Kreiner DS, Hwang SW, Easa JE, et al. An evidence-based clinical guideline for the diagnosis and treatment of lumbar disc herniation with radiculopathy. *Spine J* 2014;14:180-91.
39. Lee J, Gupta S, Price C, Baranowski AP. Low back and radicular pain: a pathway for care developed by the British Pain Society. *Br J Anaesth* 2013;111:112-20.

Copyright © 2015 Massachusetts Medical Society.